

## Operative Technique: Intersphincteric Resection

Marcus Valadão<sup>1</sup>, Daniel Cesar<sup>2</sup>, Guilherme Graziosi<sup>2</sup>, Ricardo Ary Leal<sup>3</sup>

<sup>1</sup>Doctoral student in Oncology by the National Cancer Institute; Oncologic Surgeon at II Clínica Cirúrgica of Hospital Geral de Bonsucesso – Rio de Janeiro (RJ), Brazil.

<sup>2</sup>Resident physician of General Surgery at II Clínica Cirúrgica of Hospital Geral de Bonsucesso – Rio de Janeiro (RJ), Brazil.

<sup>3</sup>Expert in Coloproctology by the Brazilian Society of Coloproctology; Surgeon at II Clínica Cirúrgica of Hospital Geral de Bonsucesso – Rio de Janeiro (RJ), Brazil.

---

Valadão M, Cesar D, Graziosi G, Leal RA. Operative Technique: Intersphincteric Resection. *J Coloproctol*, 2012;32(4): 426-429.

**ABSTRACT:** Despite the technological advances over the last years, the treatment of low rectal cancer (extraperitoneal) remains as a surgical challenge. Currently, the abdominoperineal resection is still the standard surgical treatment for most rectal lesions within 5 cm from the anal verge with well-known physical and psychological consequences. On the other hand, the introduction of intersphincteric resection in clinical practice has led to the possibility of sphincter preservation allied to satisfactory oncologic and functional outcomes in well selected cases. The present paper describes the technical steps of an intersphincteric resection for the treatment of extraperitoneal low rectal cancer.

**Keywords:** surgery; neoplasms; rectum; anal canal.

**RESUMO:** Apesar dos avanços tecnológicos dos últimos anos, o tratamento do câncer de reto inferior (extraperitoneal) continua sendo desafiador. Atualmente, a ressecção abdômino-perineal ainda é o tratamento padrão para lesões retais situadas a uma distância menor que 5 cm da margem anal, sendo bem conhecidas suas sequelas físicas e psicológicas. Em contrapartida, a introdução da ressecção interesfincteriana na prática clínica trouxe à tona a possibilidade da preservação anal aliada à obtenção de resultados oncológicos e funcionais satisfatórios em casos bem selecionados. O presente estudo tem como objetivo descrever a técnica operatória da ressecção interesfincteriana no tratamento do câncer de reto extraperitoneal.

**Palavras-chave:** cirurgia; neoplasias; reto; canal anal.

---

### INTRODUCTION

The standard surgical treatment for rectal adenocarcinoma located up to 5 cm from the anal verge is the abdominoperineal resection (APR). This happens because the length of the anal canal is from 2 to 4 cm, and the disease-free longitudinal margin should have at least 1 cm (preferentially, 2 cm)<sup>1</sup>. In order to avoid the definitive colostomy in these patients, the intersphincteric resection (IR) was first described in the 1980s, and well established in the 1990s by Schiessel et al.<sup>2</sup>. Nowadays, IR is defined as a procedure that can obtain satisfactory free margins removing the internal

sphincter partially or completely and maintaining intestinal continuity in patients with rectal cancer close to the anal canal.

According to Akasu et al.<sup>3</sup>, the meticulous performance of the technique brings satisfactory results both for the anorectal function and the oncologic outcomes for T1 and T2 tumors, without increasing local or distant recurrence rates and without the need for association with radiotherapy. In the mentioned study, 108 patients were submitted to IR. The local recurrence rate in 3 years for T1-T2 lesions was 0%, and for T3 lesions, 15%, while the distant recurrence rate for T1, T2, T3 and T4 tumors was 4, 5, 18 and

---

Study carried out at the General Surgery Department of Hospital Geral de Bonsucesso – Rio de Janeiro (RJ), Brazil.

Financing source: none.

Conflict of interest: nothing to declare.

Submitted on: dd/mm/aaaa

Approved on: dd/mm/aaaa

33%, respectively<sup>3</sup>. The use of IR in T3 and T4 lesions is still controversial, once the oncologic outcomes, in these cases, are not satisfactory when compared to the abdominoperineal resection.

The surgical planning for low rectal tumors is complex. The decision to perform IR instead of abdominoperineal resection should be discussed with the patient, and many factors should be analyzed<sup>4</sup>, such as: staging, ability to resect the tumor with free radial margins, functional implications, desire of the patient, distance from the tumor to the sphincter complex, body mass index (BMI) and anatomy of the pelvis (male x female).

### TECHNIQUE

The principle of the technique is based on the dissection of the anatomical plane between the internal sphincter, which is the prolonged muscular layer of the rectum, and the external sphincter.

Preferably, the surgical procedure is initiated by the abdominal approach, performing the high ligation of the lower mesenteric vein and the lower mesenteric artery right after the emergence of the left colic artery. Afterwards, the mobilization of the splenic flexure is performed, followed by total mesorectal excision by means of the avascular embryological plane of areolar tissue between the mesorectal fascia and the lateral endopelvic fascia until the levator ani muscle and the anorectal junction<sup>5-7</sup>.

In most rectal tumor cases that demand IR, the perineal time is necessary, which can be initiated after the mobilization of the rectum and sigmoid. A Gelpi retractor or an autostatic Lone Star<sup>®</sup> retractor (Figure 1) is placed in the anal canal to expose the mucosa, which is circumferentially opened, usually on the dentate line or 1 cm from the distal margin of the tumor. If the incision is made on the dentate line or 1 to 2 mm distal to it, the resection of the proximal half of the internal sphincter is considered. If the resection is initiated above the dentate line, but below the anorectal junction, the removal of the proximal third of the internal sphincter is considered. It is important to remember that the resection with a 1 cm longitudinal macroscopic margin should always be the goal in this stage of the procedure. Like the mucosa, the internal sphincter is circumferentially incised, and

the intersphincteric plane is dissected with the electrocautery under direct vision. To facilitate the dissection and decrease bleeding, it is possible to infiltrate a 1:200.000 adrenaline solution at this moment or before the incision. If the rectum is not closed in the abdominal stage, it should be closed with a suture bag at the occasion. Dissection proceeds until the already dissected intraperitoneal portion of the rectum is found. Then, the rectum is resected and removed through the abdomen when the access is made by laparotomy, or through the anus with videolaparoscopy. The pelvic cavity and the anal canal are irrigated with 10% iodopovidone, followed by a saline solution. The colon (especially after the confection of a colonic J pouch) is brought through the hiatus in the levator ani, and the coloanal anastomosis is performed with interrupted sutures (Figure 2). Usually the procedure is finished with a diverting loop ileostomy or colostomy to protect the anastomosis.

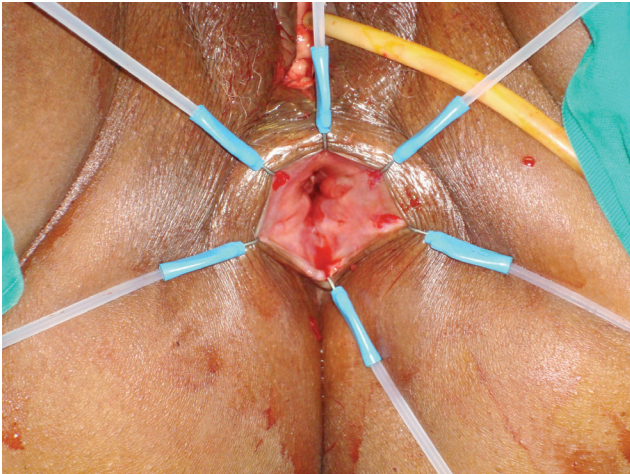
### DISCUSSION

The success of the rectal cancer treatment involves the combination of a good oncologic outcome and an acceptable quality of life for the postoperative patient. APR is considered as gold standard in the treatment of low rectal tumors<sup>8</sup>, but it generates outcomes that are followed by a compromised quality of life.

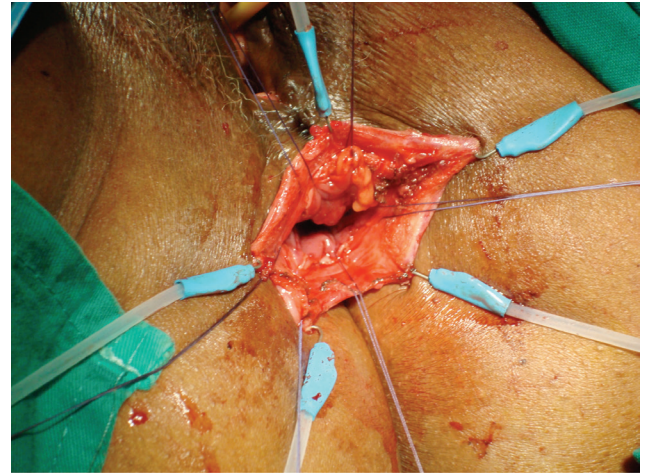
Modern surgery should not be limited to curative tumor resections, since the functional result quality of life of patients who suffer from colorectal cancer has become part of the primary treatment and has been assessed together with the oncologic outcomes. Engel et al.<sup>9</sup> reported that patients with stoma have low self-esteem, altered body image and decreased sexual and physical activity when compared to the others.

Due to these reasons, it is possible to observe that continuous efforts are being employed to preserve the anal sphincter in low rectal cancer. There is a new concept according to which the resection with a 1 cm margin for rectal tumors located near the anal margin are known for presenting oncologic outcomes comparable to larger margins<sup>10-13</sup>.

Such advances enabled the appearance of IR for tumors between 1 and 3 cm from the dentate line, and the combination of chemotherapy and neoadjuvant



**Figure 1.** Eversion of the anal mucosa with the Lone Star® retractor. The level of mucosal incision was marked with the electrocautery.



**Figure 2.** Manual coloanal anastomosis. Cardinal points visible at 12h, 3h, 6h e 9h.

radiotherapy has been used with the objective to increase the opportunity to preserve the sphincter in patients with very low rectal tumors<sup>2</sup>.

The benefits of IR compared to APR are still controversial. There are few studies comparing the oncologic outcomes of both techniques. Many of them are retrospective, but even so they pointed out there is good local control, with recurrence rates ranging from 0 and 12% after resections, preserv-

ing the anal sphincter in low and very low rectal tumors<sup>14-22</sup>.

Despite all the effort to develop new surgical techniques and preoperative therapies, some patients with rectal cancer are not eligible for IR and, inevitably, APR will be indicated, especially for those with tumors in advanced stages, next to the anal margin and little responsive to neoadjuvant treatments<sup>23-26</sup>.

## REFERENCES

1. Nicholls RJ, Hall C. Treatment of non-disseminated cancer of the lower rectum. *Br J Surg* 1996;83(1):15-8.
2. Schiessel R, Karner-Hanusch J, Herbst F, Teleky B, Wunderlich M. Intersphincteric resection for low rectal tumors. *Br J Surg* 1994;81(9):1376-8.
3. Akasu T, Takawa M, Yamamoto S, Fujita S, Moriya Y. Incidence and patterns of recurrence after intersphincteric resection for very low rectal adenocarcinoma. *J Am Coll Surg* 2007;205(5):642-7.
4. Holzer B, Urban M, Hölbling N, Feil W, Novi G, Hruby W, et al. Magnetic resonance imaging predicts sphincter invasion of low rectal cancer and influences selection of operation. *Surgery* 2003;133(6):656-61.
5. Yoo JH, Hasegawa H, Ishii Y, Nishibori H, Watanabe M, Kitajima M. Long-term outcome of per anum intersphincteric rectal dissection with direct coloanal anastomosis for lower rectal cancer. *Colorectal Dis* 2005;7(5):434-40.
6. Enker WE, Thaler HT, Cranor ML, Polyak T. Total mesorectal excision in the operative treatment of carcinoma of the rectum. *J Am Coll Surg* 1995;181(4):335-46.
7. Heald RJ, Moran BJ, Ryall RD, Sexton R, MacFarlane JK. Rectal cancer: the Basingstoke experience of total mesorectal excision, 1978-1997. *Arch Surg* 1998;133(8):894-9.
8. Rothenberger DA, Wong WD. Abdominoperineal resection for adenocarcinoma of the low rectum. *World J Surg* 1992;16(3):478-85.
9. Engel J, Kerr J, Schlesinger-Raab A, Eckel R, Sauer H, Hölzel D. Quality of life in rectal cancer patients: a four-year prospective study. *Ann Surg* 2003;238(2):203-13.
10. Andreola S, Leo E, Belli F, Bonfanti G, Sirizzotti G, Greco P, et al. Adenocarcinoma of the lower third of the rectum surgically treated with a <10-MM distal clearance: preliminary results in 35 N0 patients. *Ann Surg Oncol* 2001;8(7):611-5.
11. Minsky BD, Cohen AM, Enker WE, Paty P. Sphincter preservation with preoperative radiation therapy and coloanal anastomosis. *Int J Radiat Oncol Biol Phys* 1995;31(3):553-9.
12. Janjan NA, Khoo VS, Abbruzzese J, Pazdur R, Dubrow R, Cleary KR, et al. Tumor downstaging and sphincter

- preservation with preoperative chemoradiation in locally advanced rectal cancer: the M. D. Anderson Cancer Center experience. *Int J Radiat Oncol Biol Phys* 1999;44(5):1027-38.
13. Rouanet P, Fabre JM, Dubois JB, Dravet F, Saint Aubert B, Pradel J, et al. Conservative surgery for low rectal carcinoma after high-dose radiation. Functional and oncologic results. *Ann Surg* 1995;221(1):67-73.
  14. Rullier E, Zerbib F, Laurent C, Bonnel C, Caudry M, Saric J, et al. Intersphincteric resection with excision of internal anal sphincter for conservative treatment of very low rectal cancer. *Dis Colon Rectum* 1999;42(9):1168-75.
  15. Köhler A, Athanasiadis S, Ommer A, Psarakis E. Long-term results of low anterior resection with intersphincteric anastomosis in carcinoma of the lower one-third of the rectum: analysis of 31 patients. *Dis Colon Rectum* 2000;43(6):843-50.
  16. Rullier E, Laurent C, Bretagnol F, Rullier A, Vendrely V, Zerbib F. Sphincter-saving resection for all rectal carcinomas: the end of the 2-cm distal rule. *Ann Surg* 2005;241(3):465-9.
  17. Vorobiev GI, Odaryuk TS, Tsarkov PV, Talalakin AI, Rybakov EG. Resection of the rectum and total excision of the internal anal sphincter with smooth muscle plasty and colonic pouch for treatment of ultralow rectal carcinoma. *Br J Surg* 2004;91(11):1506-12.
  18. Saito N, Ono M, Sugito M, Ito M, Morihiko M, Kosugi C, et al. Early results of intersphincteric resection for patients with very low rectal cancer: an active approach to avoid a permanent colostomy. *Dis Colon Rectum* 2004;47(4):459-66.
  19. Turet E, Poupardin B, McNamara D, Dehni N, Parc R. Ultralow anterior resection with intersphincteric dissection-what is the limit of safe sphincter preservation? *Colorectal Dis* 2003;5(5):454-7.
  20. Prete F, Sebastiani R, Sammarco DF, Prete FP. Role of intersphincter resection among the surgical options for cancer of the distal rectum. *Chir Ital* 2001;53(6):765-72.
  21. Rullier E, Goffre B, Bonnel C, Zerbib F, Caudry M, Saric J. Preoperative radiochemotherapy and sphincter-saving resection for T3 carcinomas of the lower third of the rectum. *Ann Surg* 2001;234(5):633-40.
  22. Rullier E, Laurent C, Zerbib F, Belleannée G, Caudry M, Saric J. Conservative treatment of adenocarcinomas of the anorectal junction by preoperative radiotherapy and intersphincteral resection. *Ann Chir* 2000;125(7):618-24.
  23. Tytherleigh MG, McC Mortensen NJ. Options for sphincter preservation in surgery for low rectal cancer. *Br J Surg* 2003;90(8):922-33.
  24. Kim NK, Baik SH, Seong JS, Kim H, Roh JK, Lee KY, et al. Oncologic outcomes after neoadjuvant chemoradiation followed by curative resection with tumor-specific mesorectal excision for fixed locally advanced rectal cancer: impact of postirradiated pathologic downstaging on local recurrence and survival. *Ann Surg* 2006;244(6):1024-30.
  25. Crane CH, Skibber JM, Feig BW, Vauthey JN, Thames HD, Curley SA, et al. Response to preoperative chemoradiation increases the use of sphincter-preserving surgery in patients with locally advanced low rectal carcinoma. *Cancer* 2003;97(2):517-24.
  26. Baik SH, Kim NK, Lee KY, Sohn SK, Cho CH. Analysis of anal sphincter preservation rate according to tumor level and neoadjuvant chemoradiotherapy in rectal cancer patients. *J Gastrointest Surg* 2008;12(1):176-82.

**Correspondence to:**

Marcus Valadão  
Rua Dois de Dezembro, 78 – sala 403 – Catete  
CEP: 22220-040 – Rio de Janeiro (RJ), Brazil  
E-mail: marcusvaladao@ig.com.br